



Review

Platelet rich plasma, stromal vascular fraction and autologous conditioned serum in treatment of knee osteoarthritis



Ali Fotouhi^a, Arash Maleki^a, Sanam Dolati^{b,c}, Ali Aghebati-Maleki^d, Leili Aghebati-Maleki^{b,d,*}

^a Department of Orthopedic Surgery, Faculty of Medicine, Shahid Beheshti University of Medical Sciences, Tehran, Iran

^b Department of Immunology, Faculty of Medicine, Tabriz University of Medical Sciences, Tabriz, Iran

^c Student Research Committee, Tabriz University of Medical Sciences, Tabriz, Iran

^d Immunology Research Center, Tabriz University of Medical Sciences, Tabriz, Iran

ARTICLE INFO

Keywords:

Cell therapy
Osteoarthritis
Platelet-rich plasma
Stromal vascular fraction
Autologous conditioned serum

ABSTRACT

Osteoarthritis (OA) is a multifactorial chronic disease, causing several problems on patients, hygiene and community care systems. Conventional therapies, such as non-pharmacological mediations, systemic drug treatment and intra-articular therapies are applying previously; however, controlling and management approaches of the disease mainly remain insufficient.

Injections of intra-articular therapies directly into the joint evade conservative obstacles to joint entry, rise bioavailability and minor systemic toxicity. Current progresses in osteoarthritis management have designed better diversity of treatment approaches. Innovative treatments, such as autologous blood products and mesenchymal stem cells, are in progress. Platelet-rich plasma (PRP) is one of the several novel therapeutic approaches that stay to progress in the field of orthopedic medicine. Stromal vascular fraction (SVF) comprises a lesser amount of mesenchymal stem cells and is a treatment for OA and cartilage damage. Based on novel opinions, an innovative therapy by autologous conditioned serum (ACS) from the whole blood was settled. The inoculation of ACS into tissues has revealed clinical efficacy for the treatment of osteoarthritis and muscle injuries.

Here, we make available historical perspective of PRP, SVF, and ACS and the other existing researches on using PRP, SVF and ACS for the treatment of knee OA. In conclusion, in current years, OA stem cell therapy has rapidly progressed, with optimistic consequences in animals and human studies. Additionally, PRP, SVF and ACS injection seem to be accompanied with numerous favorable results for treatment of patients with OA.

1. Introduction

Osteoarthritis (OA) is a chronic debilitating disease of synovial joints, influencing the cartilage, ligaments, joint lining, and surrounding bones [1,2]. Knee OA is described by articular cartilage degeneration, principally owing to alterations in chondrocytes from catabolic function. The incapability of chondrocytes to tolerate this tension prevents the extracellular matrix (ECM) formation and leads to production of intermediaries, such as matrix metalloproteinases (MMPs), nitric oxide (NO), and prostaglandin E2 (PGE2), resulting in matrix degradation [3,4]. Interleukin (IL)-1 might have a catabolic effect, causing cartilage deterioration. High levels of C-reactive protein (CRP) modestly but remarkably predict those whose disease will progress [5]. Little mitotic activity and insistent metabolic imbalances in chondrocytes lead to irretrievable articular cartilage impairment, providing an environment with a restricted reparative reactions [6].

Likewise, elevated systemic inflammatory markers have a role in joint destruction. Biochemically, OA patients present an enhanced amount of water and modifications in proteoglycans (elevated chondroitin/keratin sulphate ratio).

The aetiology of OA can be primitive, due to intrinsic deficiency or secondary, because of trauma, infection [7]. The risk factors related to OA are generally personal issues, including age, gender, obesity, heredities, race/ethnicity, and dietary regimen and joint-level factors, such as damage, physical activity, type of occupation that involves joints, and muscular power [8,9]. Elements accompanying with OA have also been categorized as those that affect OA development, such as age, gender, job, weight, and those in relation to disease progression, consisting of weight and nutrition [9–11]. Age is the main independent risk factor of OA; it is becoming obvious that aging makes changes in the musculoskeletal system, contributing to the progress of OA in line with other factors [12]. There is minute or no cell division or cell death in

* Corresponding author at: Immunology Research Center, Tabriz University of Medical Sciences, Tabriz, Iran.
E-mail address: aghebatil@tbzmed.ac.ir (L. Aghebati-Maleki).

adult articular cartilage, therefore, chondrocytes are thought to be long-lived cells. Aging extremely changes chondrocyte function and matrix structure.

It appears to be an age-related reduction in the number of chondrocytes in articular cartilage [13]. Telomere shortening, can be caused by stress-induced senescence, which seems to be the much probable mechanism in cartilage damage, in which chronic inflammation and oxidative stress are further offending factors [14]. Increased production of cytokines and growth factors can contribute to tissue aging, through triggering the matrix degradation and decreasing matrix synthesis and repair [12]. Chondrocytes become less responsive to growth factors with aging, thus additionally reducing matrix synthesis and repair. Oxidative stress plays an important role in aging and in the link between aging and OA [15,16]. Increased levels of reactive oxygen species (ROS) may also contribute to the reduced sensitivity of chondrocytes to Insulin-like growth factor 1 (IGF-I) [17].

It is well known that OA is a disease with a genetic susceptibility [18]. Genes related to OA are linked to those that are involved in the process of synovial joint mechanobiology. Mutations in these genes could directly cause OA [19]. They are mainly genes that encode proteins and mediators involved in the pathways like bone morphogenetic proteins (BMPs), transforming growth factor beta (TGF- β), the wingless-type (Wnt), thyroid pathway, and apoptotic and mitochondrial DNA (mtDNA) damage-related molecules [20]. A genetic variant in *growth differentiation factor 5 (GDF5)* has been considered as the strongest genetic connotation with OA. Moreover, genetic variation also influences the joint replacement therapy on account of aseptic loosening [20].

The prevalence of hand, knee, or hip joint OA has enhanced from 21 million in 1995 to an expected 27 million amongst United States (US) adults [21]. OA can cause a decreased quality of life (QoL) and greater death rates [22]. There is no straightforward and precise blood test for the diagnosis of OA. Even though OA can be diagnosed clinically, the significance of imaging of OA in diagnosis and longitudinal evaluation of this chronic disease are well acknowledged by both rheumatologists and radiologists [23]. While basic radiographs confer the gold standard and preliminary examination imaging approach for OA diagnosis, magnetic resonance imaging (MRI) and multi detector computed tomography (MDCT) have come to be necessary for OA classification and follow-up assessment in research [24–26]. Along with MRI, kinematic and weight-bearing evaluations of the peripheral joints are currently performed by four-dimensional computed tomography (4DCT) and cone-beam CT (CBCT) [27,28]. Besides advanced cross-sectional imaging techniques, positron emission tomography (PET) examinations may reveal fundamental metabolic activities correlated with synovial inflammation in OA [27]. Radiographs remain the imaging modality of choice in OA in clinical practice. In addition, MRI is being used for detection and quantification of various OA features and has been considered as a vital investigation tool. 4DCT and CBCT have special uses once a diagnosis of fundamental motion anomaly or dynamic variations in weight-bearing condition is supposed. Clinical use of ultrasound and PET for OA imaging has been less-recognized compared with radiography and MRI [29].

2. Treatment of osteoarthritis

The specifications of OA demonstrate that there is a multi-tissue, multi-cell involvement that contribute to the development of the disease. This implies a multi-treatment attitude that distinguishes the variety of the fundamental manifestations and signs in the OA syndrome [30]. Recent treatment choices are according to a composition of patient learning, physical exercise, knee braces, and shoe orthotics; nonsteroidal anti-inflammatory drugs (NSAIDs) to mitigate pain and inflammation; intra-articular inoculations of hyaluronic acid (HA); corticosteroid injections; ultrasound-guided and fluoroscopic-guided nerve block and radio frequency ablation processes; weight regulators;

and, ultimately, aggressive joint replacement surgery [30]. Weight controlling and physical therapy are too advantageous [31]. Corticosteroid injection decreases synovitis and, therefore subside the pain in OA patients.

Endogenous hyaluronan is found in the synovial fluid and is involved in its viscoelasticity, and play a role in sustaining the tissue hydration and protein homeostasis through inhibiting great fluid movements and by performing as an osmotic buffer [31]. These types of treatments are typically palliative and only cause relief of disease symptoms and pain, preventing cartilage injury and devastation of other joint tissues [32].

Surgical treatments for knee OA include arthroscopy, cartilage repair, osteotomy, and knee arthroplasty [33]. The suitability of these techniques is determined by numerous factors, such as the location and stage of OA, comorbidities, and patients discomfort. Arthroscopic lavage and debridement are repeatedly carried out, but do not have positive impressions in the disease development [33].

Joint arthroplasty is a well-accepted, harmless, and profitable technique for treatment of progressive knee OA. Because of its irreplaceable nature, joint arthroplasty is suggested only in patients, for whom other treatment modalities have been unsuccessful or contraindicated [33,34]. Permanence of prosthetic mechanisms is restricted to about 15–20 years but endurance of unicompartamental knee arthroplasties (UKA) is generally inferior [34]. Therefore, arthroplasties should be circumvented in patients younger than 60 years. If OA is limited to one compartment, UKA or unloading osteotomy can be considered, then Total arthroplasty of the knee (TKA) with or without patellar resurfacing is observed [35]. Surgical treatment comprising fractional or complete joint knee arthroplasty and, infrequently, osteotomies are held in reserve to be carried out after failure of conventional treatments [36].

All of these methods are restricted to the repair of focal injuries. Consistent with organized clinical trials, surgical treatments have restricted long-term influence on the treatment of OA [37,38].

The use of Platelet-rich plasma (PRP), mesenchymal stem cells (MSCs), and blood products in orthopedics have improved disease course exponentially over the previous few years because of its autologous nature, proposed efficacy, and absence of side-effects [39]. PRP and Stromal vascular fraction (SVF) are progressively used frequently to treat a range of knee osteoarthritis, though its efficacy is dubious [40,41]. The cartilage is an exclusive avascular and aneural tissue that has restricted capability of self-repairing after being injured [42,43]. The aim of this article is to discuss about use of PRP, SVF and ASO to treat OA with the emphasis on the probable role of PRP and SVF in the properly restricted pharmacological approach.

2.1. Platelet-rich plasma

Platelet-rich plasma (PRP) has been used from 1950s, currently, the musculoskeletal effects of PRP have been the emphasis of substantial attention, particularly in orthopedics [44,45]. PRP is autologous plasma augmented with platelets that could be released after triggering with growth factors and cytokines [46,47]. The platelet concentration in PRP is different 5-fold from 300,000/mm³ to over 1,500,000/mm³ and these differences are as a result of dissimilarities in donors, total blood volumes, mediators designed for platelet stimulation (thrombin or calcium-chloride), amount of centrifugations, and freezing method of product [48–50]. Direct injection of PRP inside the joint could control the inflammatory response and cause healing over a long period [51,52]. PRP prevents the nuclear factor (NF)- κ B cascade, by inhibiting the stimulation of NF- κ B through I κ B α , by avoiding the activation of NF- κ B target genes [53]. NF- κ B is stimulated by IL-1 β in chondrocytes acquired from OA patients and obstructs the synthesis of anabolic pathways related genes, such as type II collagen and aggrecan [53,54]. Growth factors components in PRP have special effects such as anti-inflammatory properties and also could decrease pain. PRP comprises a

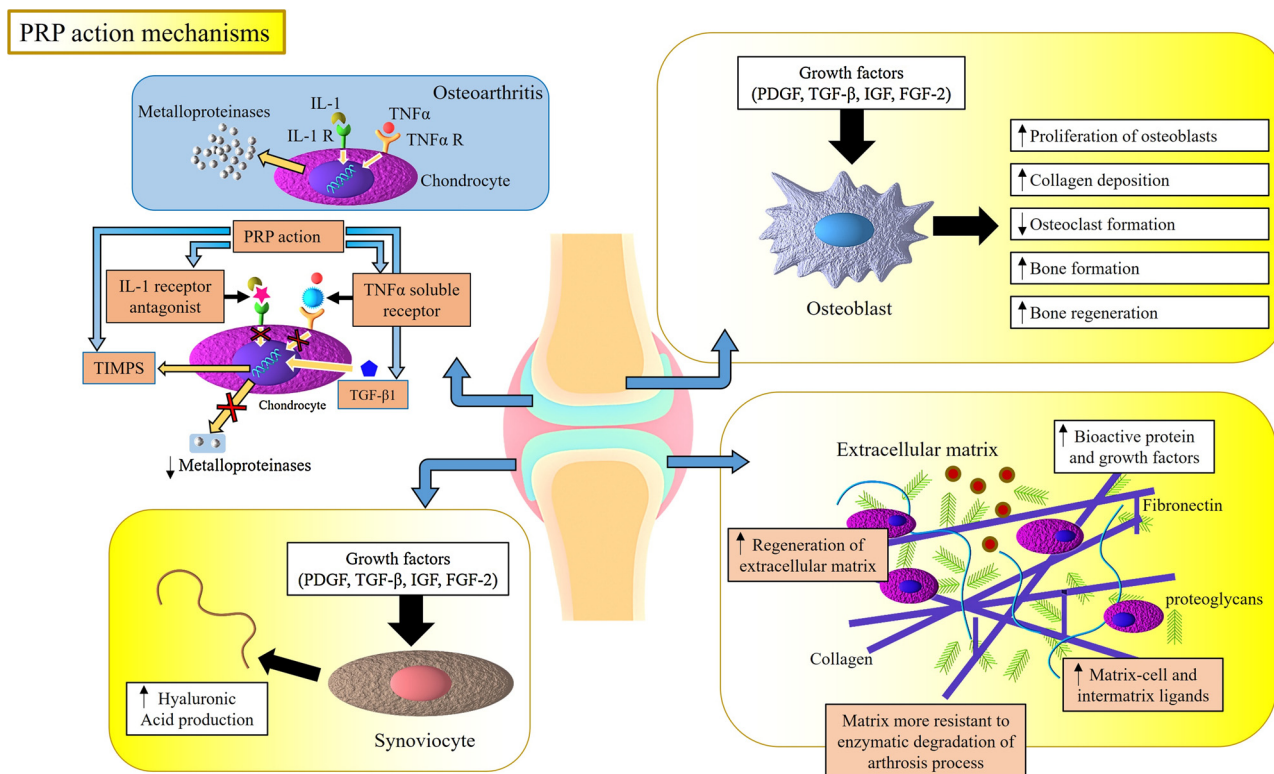


Fig. 1. Mechanism of action of Platelet-rich plasma. Tissue regeneration can be accelerated at the site of tissue injury by various growth factors produced from activated platelets. Abbreviations: PRP, platelet-rich plasma; VEGF, vascular endothelial growth factor; PDGF, platelet derived growth factor; EGF, epidermal growth factor; TNF, tumor necrosis factor; IL-1 interleukin-1; IL-1R, interleukin-1 receptor; TIMP, tissue inhibitor of metallo proteinases; PDGF, platelet-derived growth factor; IGF, insulin-like growth factor; FGF-2, fibroblast growth factor-2; TGF- β , transforming growth factor β .

group of cytokines, and growth factors, such as hepatocyte growth factor (HGF), platelet derived growth factor (PDGF), epidermal growth factor (EGF), fibroblast growth factor (FGF), IGF, and TGF- β (Fig. 1) [55,56]. HGF contributes to NF- κ B inhibition, resulting in reduction of IL-6 production and increasing the release of anti-inflammatory cytokine IL-10. TGF- β 1 suppresses the CXCR4 expression in monocytes [57,58]. IGF-1 and PDGF also prevent activation of NF- κ B [59]. Chondrocytes triggered by PRP enhance synthesis of proteoglycan and collagen, which have capacities similar to normal hyaline cartilage [51,60–62].

2.1.1. Platelet-rich plasma in the osteoarthritis knee

After administration of PRP on the knee of patients who had experienced surgery in this joint with surgical techniques, such as arthroscopic debridement and micro-fractures, clinical development was detected in the patients along with returning of the disease activity to normal levels [63]. Hart et al. executed outcomes of PRP therapy in 9 cases after arthroscopy in patients with knee OA, resulting in progress of the indicator after 6 months of treatment, which was not sustained after 1 year [64]. In one prospective cohort study with 1-year follow-up after PRP therapy for primary knee OA, 22 contributors received a 6 ml PRP injection. Pain scores reduced, while functional and clinical scores enhanced considerably after one year of treatment [65]. A randomized controlled trial investigated 78 patients with bilateral osteoarthritis, who were allotted at random to be treated with a single PRP injection, two PRP injections, or a single saline injection, as the placebo group [40]. The two PRP groups displayed substantial and comparable variations in the primary outcome, measured by visual analogue pain scale (VAS pain score) and secondary outcome, measured through Western Ontario and McMaster Universities Arthritis Index (WOMAC) [40]. The 5 additional randomized controlled trials compared PRP to hyaluronic acid. The projects concerned on the measures of pain and function to

evaluate effectiveness of the treatment, along with PRP regimen [66]. All studies indicated that Knee injury Osteoarthritis Outcome Score (KOOS), International Knee Documentation Committee (IKDC) score, and motion range were pointedly better in PRP group and also in the low-molecular-weight hyaluronic acid group [67]. PRP efficacy assessment executed through a joint ultra-sound to evaluate the articular cartilage thickness. The consequences displayed no advantage in enhancing the thickness of the articular cartilage after one year; however, the technique's sensitivity was little for revealing the minor alterations [68]. Dhollander et al., monitored patients, using MRI, who were treated with chondral lesions of the patella with cartilage debridement by settlement of a collagen membrane and PRP. It was observed that there was no change in Magnetic Resonance Observation of Cartilage Tissue Repair (MOCART) score, and lone durability of the lesions occurred [69]. In another study, MRI was used to evaluate the PRP response. Moreover, the grade of cartilage injury was assessed by changed Outer bridge Grading Scale [64]. Cartilage thickness persisted unaltered in 94% of cases and a minor enhance was documented in three cases (6%) [64].

The treatment options for OA are summarized in Table 1. Side effects of PRP are unusual and, once occurred, it is ordinarily mild and self-limited. Local signs include pain at the injection site to symptoms of arthritis. Since leukocytes flow in the infiltrate achieved by PRP, there is a grade of intra-articular inflammatory response [70]. Another unusual side effect is allergic reactions. The more serious problem is infection in the intra-articular that can be prohibited by exerting an aseptic technique. The most repeatedly described adverse event in the injected joint was arthralgia, which has a range from mild to moderate, and it is resolved in days. However, in the most severe circumstances, the pain is prolonged to weeks [71]. Additionally, hypertrophy of the renewed cartilage tissue, identified by an arthroscopy performed based on the patient's symptoms and determined by local debridement, and

Table 1
Treatment options with PRP for OA.

Study design	Duration of study	Pain outcome	Results	Reference
Prospective, double-blind, randomized trial	Six months measurements were conducted at 6 weeks, 3 months, and 6 months after treatment	VAS; WOMAC	Two PRP injections more effective than placebo (saline injection)	[40]
Nonrandomized prospective cohort study	One year	Lysholm, Tegner, IKDC	Significant improvement in Lysholm, Tegner, IKDC No significant cartilage regeneration	[64]
Prospective cohort study	One year follow-up after PRP	VAS; WOMAC	Pain scores reduced Functional scores enhanced	[65]
Five pilot patients report.	Two years	MOCART	The favorable clinical outcome of this technique was not confirmed by the MRI findings	[69]

IKDC, International Knee Documentation Committee; MOCART, Magnetic Resonance Observation of Cartilage Tissue Repair; MRI, Magnetic Resonance Imaging; OA, Osteoarthritis; PRP, Platelet-rich plasma; VAS, Visual Analogue Pain Scale; WOMAC, Western Ontario and McMaster Universities Arthritis Index.

also rash were reported in some studies after the injection [69]. Systemic indications and infections were not reported in the evaluated studies [72].

2.2. Autologous stromal vascular fraction (SVF)

Newly, it was revealed that Adipose tissue-derived stem cells (ADSCs) have an excessive therapeutic potential in regenerative medicine. Animal studies using ADSCs established the effectiveness of ADSCs in treatment of OA and other orthopedic circumstances [73,74]. Adipose tissue is attained through liposuction after local anesthesia. Autologous Stromal vascular fraction (SVF) obtained from adipose tissue as a treatment choice comprise 1–4% MSCs along with other cell types and contribute to tissue renewal by impressing pre-adipocytes, vascular adventitial cells, macrophages, red blood cells, fibroblasts, extracellular matrix (ECM), and regulatory T cells [75–77]. The anti-inflammatory, immunomodulatory, and pain lessening effects are also partially contributed by soluble factors secreted from the SVF or ADSCs [78]. ADSCs secrete numerous significant soluble factors, such as HGF, VEGF, NGF, EGF, FGF, and TGF- β [59,79]. ADSCs treated with PRP impede VEGF production, thus the ADSC's differentiation to chondrocytes is hampered [80].

2.2.1. Preparation of autologous adipose SVF

With the aim of attaining autologous SVF, at first liposuction is done and lipoaspirate is prepared. Afterwards, collagenase breaks down the lipoaspirates. After the matrix broken, MSCs are released from the adipose tissue [81,82]. These MSCs are named ADSCs. Subsequently, ADSCs are sequestered by the centrifugation-and-dilution method, and collagenase is wash away. The final product is reflected to be SVF (Fig. 2) [68,69].

2.2.2. Autologous stromal vascular fraction in osteoarthritis

One of the main problems relating to adipose SVF in orthopedic situations is the absence of accessibility of randomized controlled trials. Because of such restraint, in spite of successful consequences described by studies, it is not recognized as a conventional medical treatment, not up till now [83]. In one study, Pak described a case series of treating patients with SVF and renewing cartilage-like tissue [84]. Percutaneously injected SVF, with PRP and HA, into the knee joints display that VAS for pain, functional rating index (FRI), and range of motion (ROM) to be improved accompanied by MRI confirmation of cartilage regeneration [84]. In 2013, one cohort study stated the efficiency of the treatment at 3 months to be 65%, without expansion of tumors, but several side effects, such as swelling and tendonitis were reported [85]. Koh et al. in 2013, performed a case series study, in which the patients with knees OA received autologous SVF with autologous PRP percutaneously after arthroscopic debridement and lavage [86]. The patients were assessed with WOMAC score, VAS score, Lysholm knee scoring scales, and MRI. After a few months, patients developed all criteria,

with no severe difficulties [86]. In another study by Koh et al., the clinical consequences and second-look arthroscopy results were compared between an autologous SVF/PRP injection group and a PRP-only group [87]. After 2 years, the consequences displayed that the autologous SVF/PRP group exhibited considerably bigger development than the PRP-only group, as evaluated by KOOS subscales for pain and signs, VAS for pain, and second-look arthroscopic assessment [87]. Koh et al. in 2014, performed a case series of second-look arthroscopy in patients with knee OA [88]. Primarily, the patients experienced arthroscopic investigations with debridement and lavage. Later, autologous SVF and autologous PRP were injected. Approximately 12.7 months after treatment, second-look arthroscopy was done. The results presented that the mean Tegner activity level scales and IKDC developed significantly [88].

Kim et al. investigated the efficiency of autologous SVF alone and compared with autologous SVF with fibrin glue [89]. After nearby 28 months, the average Tegner activity level scale and IKDC score in two groups were enhanced considerably. Though, in second-look arthroscopies, the International Cartilage Repair Society (ICRS) score was improved in the adipose SVF with fibrin glue group [89]. In 2016, Pak et al. reported a case series study, in which adding autologous ECM together with the SVF could be functioning after being used with autologous PRP and HA [90]. Three months after treatment, wholly indications, assessed by VAS pain score, ROM, and FRI, were developed. Furthermore, evaluation of pre-treatment and post-treatment MRI data confirmed cartilage-like tissue regeneration (Table 2) [90].

2.3. Autologous conditioned serum (ACS)

Exposure of blood leukocytes to pyrogen free surfaces stimulates a set of anti-inflammatory cytokines, containing interleukin-1 receptor antagonist (IL-1ra), and several growth factors, in the liquid phase of blood [91]. The first use of cytokine inhibitors and growth factors as therapeutic agents was recommended in the late 1970s and early 1980s. IL-1 seems to be of superior significance in orthopedic diseases. IL-1ra is a competitive antagonist receptor of IL-1 [92,93]. One hypothesis is that the concentration of local IL-1ra is low in degenerative disease to impede the devastation of joint structures [94,95]. It is currently evident that other anti-inflammatory cytokines and soluble receptors, which demonstrate difference dissociation rates for IL-1 α , IL-1 β , and IL-1ra, can influence IL-1 receptor signaling and inflammatory circumstances [96]. Isolated human monocytes could produce IL-1ra after being stimulated by surface bound of immunoglobulin G (IgG), along with phorbol myristate acetate (PMA), lipopolysaccharide (LPS), IL-1, and tumor necrosis factor-alpha (TNF α) [97,98]. Meijer et al. developed autologous conditioned serum (ACS) advertised as 'Orthokine', a medicinal method (a syringe) used to made ACS improved with anti-inflammatory cytokines [99]. A novel method has been promoted that attains IL-1ra stimulation without the requisite to coat surfaces with IgG [99]. The production of ACS rich in IL-1ra is conducted by incubation

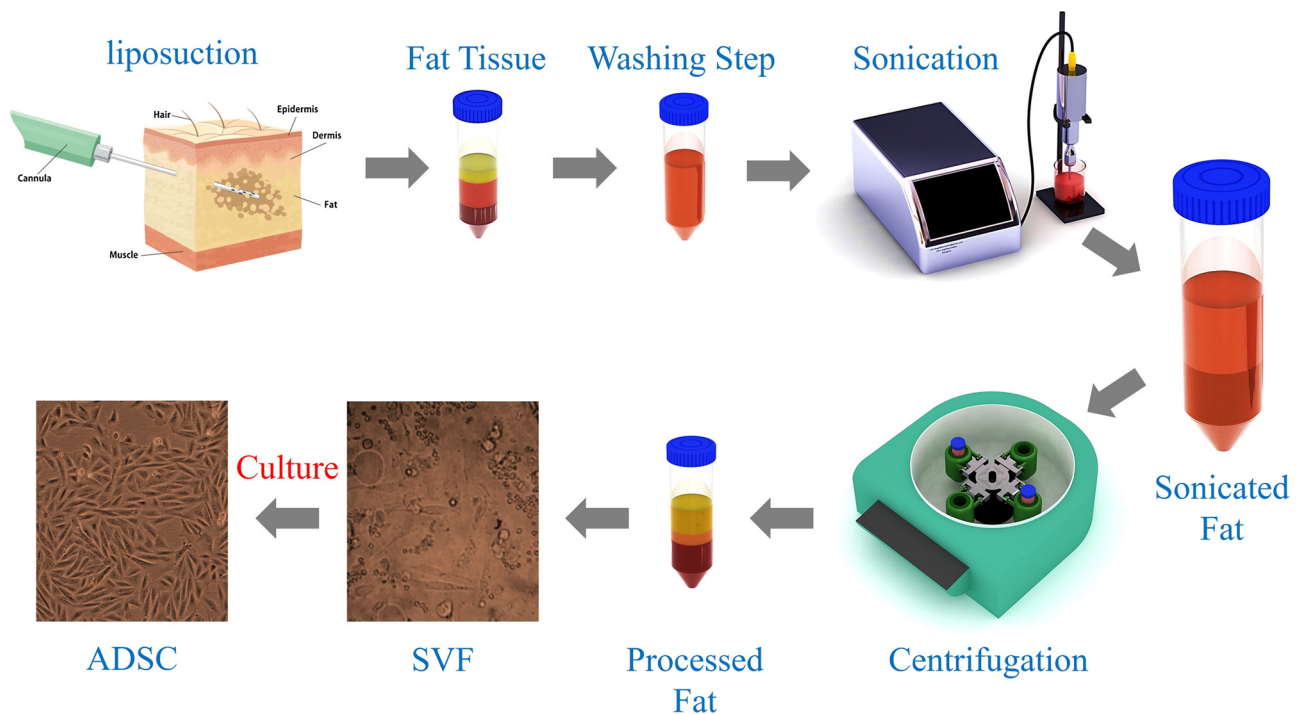


Fig. 2. Stromal vascular fraction (SVF) isolation procedure. This protocol describes procedures for isolating of highly purified stromal stem cells from human adipose tissue.

into a syringe of 50–60 ml of venous blood [100]. The blood is recuperated and centrifuged after incubation for 24 h at 37 °C. This method stimulates a quick production of IL-1ra [100]. Leukocytes produce increased levels of IL-1ra, which is accumulated in the serum. After centrifugation and taking out, ACS is aliquoted and, whichever stockpiled up to usage, is injected into the affected section of the animal or human (Fig. 3) [91]. The products, that are released via mononuclear cells and platelets over ACS production, are partially derivative from intracellular reservoirs and somewhat produced de novo [101].

2.3.1. Autologous conditioned serum in osteoarthritis

Rutgers et al., to study the amount of intra-articular injection of ACS

to cause cytokine level alterations in synovial fluid (SF), assessed the in vitro effect of Orthokine on cartilage proteoglycan metabolism by 48 full-thickness osteoarthritic cartilage explants, derivative from the femoral condyles of OA patients experiencing a total knee arthroplasty [102]. The In vitro ACS did not appear to have a direct effect on cartilage metabolism, maybe due to quick vanishing of cytokines from the SF after injection. Actually, ACS had a short intra-articular half-life with rapid clearance from the joint.

Furthermore, along with the rise in anti-inflammatory cytokines, pro-inflammatory cytokines were considerably enhanced, contrary to former examinations. Finally, throughout the course of treatment, no important changes in cytokine levels in SF was observed, in spite of

Table 2
Treatment options with SVF for OA.

Study design	Duration of study	Intervention treatment	Pain outcome	Results	Reference
Case series	12 weeks post-treatment follow-up	SVF + PRP + HA	VAS; FRI; ROM	MRI confirmation of cartilage regeneration pain, and functional status improved	[84]
Cohort study	Three months	SVF + PRP + HA	Lysholm, Tegner, IKDC	Significant improvement in Lysholm, Tegner, IKDC,	[85]
Case series	Two years	SVF + PRP	VAS; WOMAC; Lysholm	no significant cartilage regeneration VAS/function/MRI improvements	[86]
Comparative study	Two years	SVF + PRP vs. PRP-only group (second-look arthroscopy results)	VAS; KOOS	SVF/PRP group exhibited development than the PRP-only group	[87]
Case series	About 12.7 months	SVF + PRP (second-look arthroscopy results)	Tegner; IKDC	About 94% of patients had excellent clinical improvement	[88]
Comparative study	Twenty-eight months	SVF alone vs. SVF with fibrin glue (second-look arthroscopy results)	Tegner; IKDC ; ICRS	Enhanced Tegner scale and IKDC score in two groups ICRS score were improved in the adipose SVF with fibrin glue group	[89]
Case series	Three months	SVF + HA + PRP	VAS; FRI; ROM	Pain, and functional status improved MRI data confirmed cartilage-like tissue regeneration	[90]

FRI, Functional Rating Index; HA, Hyaluronic Acid; ICRS, International Cartilage Repair Society; IKDC, International Knee Documentation Committee; MRI, Magnetic Resonance Imaging; OA, Osteoarthritis; PRP, Platelet-rich plasma; ROM, Range Of Motion; SVF, Stromal Vascular Fraction; VAS, Visual Analogue Pain Scale; WOMAC, Western Ontario and McMaster Universities Arthritis Index.

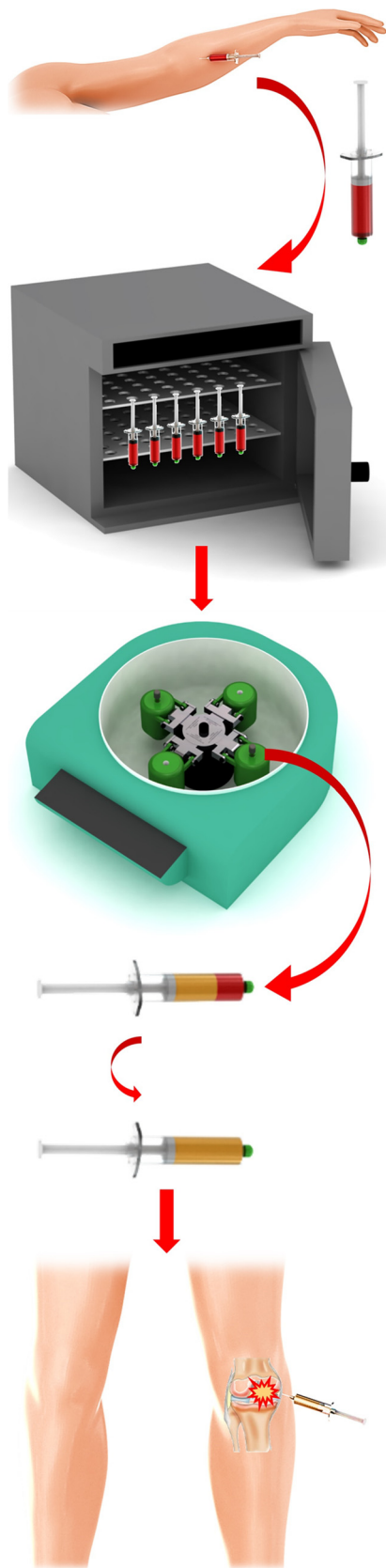


Fig. 3. Processing of Autologous Conditioned Serum. Autologous conditioned serum (ACS) is produced by incubating venous blood in the presence of medical grade glass beads. Following centrifugation and extraction, ACS is allocated and either stored until use or injected into the affected area of the human patient.

recurrent ACS injection.

In one clinical trial study, two groups of professional athletes were treated with either standard of care ActoveginR plus TraumeelR injections (5 mL) into the injury site, or with ACS injections (2.5 mL plus 2.5 mL saline) [103]. No local or systemic side effects were identified in both groups. The outcomes displayed a considerable trend to less reclamation time in the ACS group compared with the group with standard treatment [103].

Injecting ACS into damaged muscle is impressive and well endured, and accelerates the muscle renewal in research laboratory mice and human athletes. Patients with knee OA were included in an intention-to-treat (ITT) analysis, in which intra-articular injections of ACS were compared with intra-articular hyaluronan and placebo (saline) [104]. Local side effects were observed, including pain, swelling, or effusion [105,106].

In all treatment groups, intra-articular injections eventuated in a major decrease in WOMAC score. Nevertheless, reactions to ACS were considerably greater. Only local adverse events occurred. The study indicated that ACS had an obvious clinical and substantial therapeutic influence on the main signs of knee OA after six months. Due to its autologous source, the possible risk of rising adverse effects after treatment with ACS is slight. Orthokine-derived ACS decreased pain and raised function and flexibility for up to 2 years in primary knee OA [104].

3. Limitations of practical applications of PRP, SVF, and ACS

There are numerous limitations of practical applications of PRP, SVF and ACS. With regard to PRP, minute basic investigations and insufficient preclinical studies have been conducted to evaluate their therapeutic potentials. Some studies, at present, have produced outstanding results, but most were restricted case studies or series [107,108]. There is little agreement concerning PRP production and categorization. Some studies have described the development of an antibody to bovine thrombin, which was the stimulator of platelet activation [108]. The advantageous properties of SVF have also been confirmed methodically both in vitro and in vivo. In case of SVF, good manufacturing practices (GMPs) are required for manufacturing of human stem cells to be used in clinic. Furthermore, some researches have reported that SVF could have a probable risk of transformation to malignant cells [109,110]. The use of ACS in tendon damages may be a hopeful biomolecular treatment, nonetheless, the absence of returning the power to a normal level after ACS incubation, restricts the possible application in human trials [100].

4. Conclusion and future perspective

Knee OA is a long-lasting orthopedic disease that considerably decreases the patient's quality of life. In current years, stem cell utilization to treat OA has quickly progressed, with hopeful consequences in animals and human studies [75]. PRP resulted favorably in declining pain and joint function in knee OA. There is not a steady indication about the function of PRP on the cartilage, as assessed through imaging [111]. Even though PRP appears to have beneficial effects, further attentions are still essential in understanding the exact outcomes. The assessment of the outcomes is complex, since there is no calibration in the collection and use of PRP regimen. Consequently, more randomized future studies with suitable plan are required to approve the definite PRP role in OA [111]. Autologous SVF injection is a safe and beneficent technique for treating osteoarthritis. The efficacy of transplantation is obviously developed after 6 months [112]. Pain is considerably decreased after therapy, and the life of subjects gains better quality [113]. However, it has been proposed that treatment with SVF is a slightly aggressive therapy for OA patients. ACS has been revealed to be an efficient and well-endured treatment choice in human knee OA. The autologous generation of ACS by the Orthokine (human) or IRAP

(equine) system causes an increased volumes of anti-inflammatory cytokines and growth factors [91,104]. One of the suitable outcomes, concerning the effects of the SVF and PRP injection, is that the patient can sense pain decline [114]. The second effect of SVF and PRP injection is the stimulation of cartilage growth at the injected site. Autologous SVF injection in combination with PRP is a safe and profitable technique for treating grade II and III OA [30]. It was reported that, generally, 100% of patients were satisfied with this technique. Pain was extremely decreased after 3 months, and the results demonstrated that the cartilage layer slowly became thicker at 3 and 6 months after injection. Moreover, a number of damaged cartilage sites were renewed [59]. The outcomes establish that ACS is exceedingly effective and well-tolerated in the managing of chronic knee OA [100]. In consideration of all, it can be concluded that PRP, SVF and ASC injection have various good results for patients with O, along with little adverse effects. Further investigations should focus on these methods to decrease and control the unwanted outcomes.

Conflict of interests

Authors declare no conflict of interest.

Acknowledgements

The authors would like to thank Immunology Research Center, Tabriz University of Medical Sciences and Department of Orthopedic Surgery, Shahid Beheshti University of Medical Sciences for supporting the work.

References

- [1] A. Litwic, M.H. Edwards, E.M. Dennison, C. Cooper, Epidemiology and burden of osteoarthritis, *Br. Med. Bull.* 105 (1) (2013) 185–199.
- [2] T. Neogi, Y. Zhang, Epidemiology of osteoarthritis, *Rheum. Dis. Clin.* 39 (1) (2013) 1–19.
- [3] J.A. Buckwalter, C. Saltzman, T. Brown, The impact of osteoarthritis: implications for research, *Clin. Orthop. Relat. Res.* 427 (2004) S6–S15.
- [4] M. Ochi, Y. Uchio, K. Kawasaki, S. Wakitani, J. Iwasa, Transplantation of cartilage-like tissue made by tissue engineering in the treatment of cartilage defects of the knee, *Bone Joint J.* 84 (4) (2002) 571–578.
- [5] X. Xie, V. Ulici, P.G. Alexander, Y. Jiang, C. Zhang, R.S. Tuan, Platelet-rich plasma inhibits mechanically induced injury in chondrocytes, *Arthrosc.: J. Arthrosc. Relat. Surg.* 31 (6) (2015) 1142–1150.
- [6] J.S. Georgy, L.P. Lai, T.P. Stitik, R.D. Desai, C. Koon, S. Kumbar, B. Chen, P.M. Foye, Role of PRP in the treatment of knee osteoarthritis, *Curr. Phys. Med. Rehabil. Rep.* 4 (2) (2016) 138–144.
- [7] M. Shahid, R. Kundra, Platelet-rich plasma (PRP) for knee disorders, *EFORT Open Rev.* 2 (2) (2017) 28–34.
- [8] R.K. Chaganti, N.E. Lane, Risk factors for incident osteoarthritis of the hip and knee, *Curr. Rev. Musculoskelet. Med.* 4 (3) (2011) 99.
- [9] R. Plotnikoff, N. Karunamuni, E. Lytvyak, C. Penfold, D. Schopflocher, I. Imayama, S.T. Johnson, K. Raine, Osteoarthritis prevalence and modifiable factors: a population study, *BMC Public Health* 15 (1) (2015) 1195.
- [10] M. Maleki-Fischbach, J.M. Jordan, New developments in osteoarthritis. Sex differences in magnetic resonance imaging-based biomarkers and in those of joint metabolism, *Arthritis Res. Ther.* 12 (4) (2010) 212.
- [11] V.K. Srikanth, J.L. Fryer, G. Zhai, T.M. Winzenberg, D. Hosmer, G. Jones, A meta-analysis of sex differences prevalence, incidence and severity of osteoarthritis, *Osteoarthr. Cartil.* 13 (9) (2005) 769–781.
- [12] R.F. Loeser, Age-related changes in the musculoskeletal system and the development of osteoarthritis, *Clin. Geriatr. Med.* 26 (3) (2010) 371–386.
- [13] A. Heijink, A.H. Gomoll, H. Madry, M. Drobnic, G. Filardo, J. Espregueira-Mendes, C.N. Van Dijk, Biomechanical considerations in the pathogenesis of osteoarthritis of the knee, *Knee Surg. Sports Traumatol. Arthrosc.* 20 (3) (2012) 423–435.
- [14] R.F. Loeser, Aging and osteoarthritis: the role of chondrocyte senescence and aging changes in the cartilage matrix, *Osteoarthr. Cartil.* 17 (8) (2009) 971–979.
- [15] R.F. Loeser, C.S. Carlson, M.D. Carlo, A. Cole, Detection of nitrotyrosine in aging and osteoarthritic cartilage: correlation of oxidative damage with the presence of interleukin-1 β and with chondrocyte resistance to insulin-like growth factor 1, *Arthritis Rheumatol.* 46 (9) (2002) 2349–2357.
- [16] K. Yudoh, N. van Trieu, H. Nakamura, K. Hongo-Masuko, T. Kato, K. Nishioka, Potential involvement of oxidative stress in cartilage senescence and development of osteoarthritis: oxidative stress induces chondrocyte telomere instability and downregulation of chondrocyte function, *Arthritis Res. Ther.* 7 (2) (2005) R380.
- [17] W. Yin, J.-I. Park, R.F. Loeser, Oxidative stress inhibits insulin-like growth factor-I induction of chondrocyte proteoglycan synthesis through differential regulation of phosphatidylinositol 3-Kinase-Akt and MEK-ERK MAPK signaling pathways, *J. Biol. Chem.* 284 (46) (2009) 31972–31981.
- [18] H. Madry, F.P. Luyten, A. Facchini, Biological aspects of early osteoarthritis, *Knee Surg. Sports Traumatol. Arthrosc.* 20 (3) (2012) 407–422.
- [19] L.J. Sandell, Etiology of osteoarthritis: genetics and synovial joint development, *Nat. Rev. Rheumatol.* 8 (2) (2012) 77.
- [20] A.M. Valdes, T.D. Spector, The clinical relevance of genetic susceptibility to osteoarthritis, *Best Pract. Res. Clin. Rheumatol.* 24 (1) (2010) 3–14.
- [21] R.C. Lawrence, D.T. Felson, C.G. Helmick, L.M. Arnold, H. Choi, R.A. Deyo, S. Gabriel, R. Hirsch, M.C. Hochberg, G.G. Hunder, Estimates of the prevalence of arthritis and other rheumatic conditions in the United States: part II, *Arthritis Rheumatol.* 58 (1) (2008) 26–35.
- [22] D.T. Felson, R.C. Lawrence, P.A. Dieppe, R. Hirsch, C.G. Helmick, J.M. Jordan, R.S. Kington, N.E. Lane, M.C. Nevitt, Y. Zhang, Osteoarthritis: new insights. Part 1: the disease and its risk factors, *Ann. Intern. Med.* 133 (8) (2000) 635–646.
- [23] A. Guermazi, D. Hayashi, F.W. Roemer, D.T. Felson, Osteoarthritis: a review of strengths and weaknesses of different imaging options, *Rheum. Dis. Clin.* 39 (3) (2013) 567–591.
- [24] R.D. Altman, G. Gold, Atlas of individual radiographic features in osteoarthritis, revised, *Osteoarthr. Cartil.* 15 (2007) A1–A56.
- [25] J.-P. Raynaud, J. Martel-Pelletier, B. Haraoui, D. Choquette, M. Dorais, L.M. Wildi, F. Abram, J.-P. Pelletier, C.L.S. Group, Risk factors predictive of joint replacement in a 2-year multicentre clinical trial in knee osteoarthritis using MRI: results from over 6 years of observation, *Ann. Rheum. Dis.* 70 (8) (2011) 1382–1388.
- [26] S. Demehri, N. Hafezi-Nejad, J.A. Carrino, Conventional and novel imaging modalities in osteoarthritis: current state of the evidence, *Curr. Opin. Rheumatol.* 27 (3) (2015) 295–303.
- [27] N. Hafezi-Nejad, B. Zikria, J. Eng, J.A. Carrino, S. Demehri, Predictive value of semi-quantitative MRI-based scoring systems for future knee replacement: data from the osteoarthritis initiative, *Skeletal Radiol.* 44 (11) (2015) 1655–1662.
- [28] F.W. Roemer, C.K. Kwok, M.J. Hannon, D.J. Hunter, F. Eckstein, Z. Wang, R.M. Boudreau, M.R. John, M.C. Nevitt, A. Guermazi, Can structural joint damage measured with MR imaging be used to predict knee replacement in the following year? *Radiology* 274 (3) (2014) 810–820.
- [29] S. Demehri, A. Guermazi, C.K. Kwok, Diagnosis and longitudinal assessment of osteoarthritis: review of available imaging techniques, *Rheum. Dis. Clin.* 42 (4) (2016) 607–620.
- [30] N. Gibbs, R. Diamond, E.O. Sekyere, W.D. Thomas, Management of knee osteoarthritis by combined stromal vascular fraction cell therapy, platelet-rich plasma, and musculoskeletal exercises: a case series, *J. Pain Res.* 8 (2015) 799.
- [31] A.J. Detterline, J.L. Goldstein, J.-P.H. Rue, B.R. Bach, Evaluation and treatment of osteochondritis dissecans lesions of the knee, *J. Knee Surg.* 21 (02) (2008) 106–115.
- [32] H. Bansal, K. Comella, J. Leon, P. Verma, D. Agrawal, P. Koka, T. Ichim, Intra-articular injection in the knee of adipose derived stromal cells (stromal vascular fraction) and platelet rich plasma for osteoarthritis, *J. Transl. Med.* 15 (1) (2017) 141.
- [33] K. Rönn, N. Reischl, E. Gautier, M. Jacobi, Current surgical treatment of knee osteoarthritis, *Arthritis* 2011 (2011).
- [34] E. Koskinen, P. Paavolainen, A. Eskelinen, P. Pulkkinen, V. Remes, Unicompartmental knee replacement for primary osteoarthritis: a prospective follow-up study of 1,819 patients from the Finnish arthroplasty register, *Acta Orthop.* 78 (1) (2007) 128–135.
- [35] T. Borus, T. Thornhill, Unicompartmental knee arthroplasty, *J. Am. Acad. Orthop. Surg.* 16 (1) (2008) 9–18.
- [36] C.F. Kellett, P.J. Boscainos, A.E. Gross, Surgical options for articular defects of the knee, *Expert Rev. Med. Devices* 3 (5) (2006) 585–593.
- [37] A. Kirkley, T.B. Birmingham, R.B. Litchfield, J.R. Giffin, K.R. Willits, C.J. Wong, B.G. Feagan, A. Donner, S.H. Griffin, L.M. D'asciano, A randomized trial of arthroscopic surgery for osteoarthritis of the knee, *New Engl. J. Med.* 359 (11) (2008) 1097–1107.
- [38] W. Kanchanatawan, A. Arirachakaran, K. Chaijenkij, N. Prasathaporn, M. Boonard, P. Piyapittayanun, J. Kongtharvonskul, Short-term outcomes of platelet-rich plasma injection for treatment of osteoarthritis of the knee, knee surgery, sports traumatology, *Arthroscopy* 24 (5) (2016) 1665–1677.
- [39] K.S. Lee, J.J. Wilson, D.P. Rabago, G.S. Baer, J.A. Jacobson, C.G. Borrero, Musculoskeletal applications of platelet-rich plasma: fad or future? *Am. J. Roentgenol.* 196 (3) (2011) 628–636.
- [40] S. Patel, M.S. Dhillon, S. Aggarwal, N. Marwaha, A. Jain, Treatment with platelet-rich plasma is more effective than placebo for knee osteoarthritis: a prospective, double-blind, randomized trial, *Am. J. Sports Med.* 41 (2) (2013) 356–364.
- [41] V. Tantuway, S.M. Johar, M. Rassiwal, N. Shaji, F. Bandookwala, Use of autologous adipose tissue derived stromal vascular fraction in treatment of knee osteoarthritis and chondral lesions, *J. Evid. Based Med. Healthc.* 2 (41) (2015) 7085–7098.
- [42] J.C. Schrama, B. Espehaug, G. Hallan, L.B. Engesaeter, O. Furnes, L.I. Havelin, B.T.S. Fevang, Risk of revision for infection in primary total hip and knee arthroplasty in patients with rheumatoid arthritis compared with osteoarthritis: a prospective, population-based study on 108,786 hip and knee joint arthroplasties from the Norwegian arthroplasty register, *Arthritis Care Res.* 62 (4) (2010) 473–479.
- [43] F. Thorey, F. Reck, H. Windhagen, G. von Lewinski, Influence of bone density on total hip resurfacing arthroplasty in patients with osteonecrosis of the femoral head—a radiological analysis, *Technol. Health Care* 16 (3) (2008) 151–158.
- [44] F. Smets, J.-L. Croisier, B. Forthomme, J.-M. Crielaard, J.-F. Kaux, Applications

- cliniques du plasma riche en plaquettes (PRP) dans les lésions tendineuses: revue de la littérature, *Sci. Sports* 27 (3) (2012) 141–153.
- [45] X. Xie, C. Zhang, R.S. Tuan, Biology of platelet-rich plasma and its clinical application in cartilage repair, *Arthritis Res. Ther.* 16 (1) (2014) 204.
- [46] I. Andia, M. Sánchez, N. Maffulli, Joint pathology and platelet-rich plasma therapies, *Expert Opin. Biol. Ther.* 12 (1) (2012) 7–22.
- [47] I. Andia, N. Maffulli, Platelet-rich plasma for managing pain and inflammation in osteoarthritis, *Nat. Rev. Rheumatol.* 9 (12) (2013) 721–730.
- [48] E.A. Sundman, B.J. Cole, L.A. Fortier, Growth factor and catabolic cytokine concentrations are influenced by the cellular composition of platelet-rich plasma, *Am. J. Sports Med.* 39 (10) (2011) 2135–2140.
- [49] P. Ornetti, G. Nourissat, F. Berenbaum, J. Sellam, P. Richette, X. Chevalier, Does platelet-rich plasma have a role in the treatment of osteoarthritis? *Joint Bone Spine* 83 (1) (2016) 31–36.
- [50] L.A. Fortier, C.H. Hackett, B.J. Cole, The effects of platelet-rich plasma on cartilage: basic science and clinical application, *Oper. Tech. Sports Med.* 19 (3) (2011) 154–159.
- [51] Y. Sun, Y. Feng, C. Zhang, S. Chen, X. Cheng, The regenerative effect of platelet-rich plasma on healing in large osteochondral defects, *Int. Orthop.* 34 (4) (2010) 589–597.
- [52] Y. Zhu, M. Yuan, H. Meng, A. Wang, Q. Guo, Y. Wang, J. Peng, Basic science and clinical application of platelet-rich plasma for cartilage defects and osteoarthritis: a review, *Osteoarthr. Cartil.* 21 (11) (2013) 1627–1637.
- [53] G.M. van Buul, W.L. Koevoet, N. Kops, P.K. Bos, J.A. Verhaar, H. Weinans, M.R. Bernsen, G.J. van Osch, Platelet-rich plasma release inhibits inflammatory processes in osteoarthritic chondrocytes, *Am. J. Sports Med.* 39 (11) (2011) 2362–2370.
- [54] C.-C. Wu, W.-H. Chen, B. Zao, P.-L. Lai, T.-C. Lin, H.-Y. Lo, Y.-H. Shieh, C.-H. Wu, W.-P. Deng, Regenerative potentials of platelet-rich plasma enhanced by collagen in retrieving pro-inflammatory cytokine-inhibited chondrogenesis, *Biomaterials* 32 (25) (2011) 5847–5854.
- [55] P.R. Amable, R.B.V. Carias, M.V.T. Teixeira, Í. da Cruz Pacheco, R.J.F.C. do Amaral, J.M. Granjeiro, R. Borojevic, Platelet-rich plasma preparation for regenerative medicine: optimization and quantification of cytokines and growth factors, *Stem Cell Res. Ther.* 4 (3) (2013) 67.
- [56] B. Hamilton, J.L. Tol, W. Knez, H. Chalabi, Exercise and the platelet activator calcium chloride both influence the growth factor content of platelet-rich plasma (PRP): overlooked biochemical factors that could influence PRP treatment, *Br. J. Sports Med.* 49 (2015) 957–960.
- [57] P. Bendinelli, E. Matteucci, G. Dogliotti, M.M. Corsi, G. Banfi, P. Maroni, M.A. Desiderio, Molecular basis of anti-inflammatory action of platelet-rich plasma on human chondrocytes: mechanisms of NF- κ B inhibition via HGF, *J. Cell. Physiol.* 225 (3) (2010) 757–766.
- [58] G.M. Coudriet, J. He, M. Trucco, W.M. Mars, J.D. Piganelli, Hepatocyte growth factor modulates interleukin-6 production in bone marrow derived macrophages: implications for inflammatory mediated diseases, *PLoS One* 5 (11) (2010) e15384.
- [59] P. Van Pham, K. Hong-Thien Bui, D. Quoc Ngo, L. Tan Khuat, N. Kim Phan, Transplantation of nonexpanded adipose stromal vascular fraction and platelet-rich plasma for articular cartilage injury treatment in mice model, *J. Med. Eng.* 2013 (2013).
- [60] G. Milano, E.S. Passino, L. Deriu, G. Careddu, L. Manunta, A. Manunta, M.F. Saccomanno, C. Fabbriani, The effect of platelet rich plasma combined with microfractures on the treatment of chondral defects: an experimental study in a sheep model, *Osteoarthr. Cartil.* 18 (7) (2010) 971–980.
- [61] J.P. Krüger, S. Hondke, M. Endres, A. Pruss, A. Siclari, C. Kaps, Human platelet-rich plasma stimulates migration and chondrogenic differentiation of human subchondral progenitor cells, *J. Orthop. Res.* 30 (6) (2012) 845–852.
- [62] H.R. Lee, K.M. Park, Y.K. Joung, K.D. Park, S.H. Do, Platelet-rich plasma loaded in situ-formed hydrogel enhances hyaline cartilage regeneration by CB1 upregulation, *J. Biomed. Mater. Res. A* 100 (11) (2012) 3099–3107.
- [63] A. Gobbi, G. Karnatzikos, V. Mahajan, S. Malchira, Platelet-rich plasma treatment in symptomatic patients with knee osteoarthritis: preliminary results in a group of active patients, *Sports Health* 4 (2) (2012) 162–172.
- [64] R. Hart, A. Safi, M. Komzák, P. Jajtner, M. Puskeiler, P. Hartová, Platelet-rich plasma in patients with tibiofemoral cartilage degeneration, *Arch. Orthop. Trauma Surg.* 133 (9) (2013) 1295–1301.
- [65] B. Halpern, S. Chaudhury, S.A. Rodeo, C. Hayter, E. Bogner, H.G. Potter, J. Nguyen, Clinical and MRI outcomes after platelet-rich plasma treatment for knee osteoarthritis, *Clin. J. Sport Med.* 23 (3) (2013) 238–239.
- [66] K.-V. Chang, C.-Y. Hung, F. Aliwarga, T.-G. Wang, D.-S. Han, W.-S. Chen, Comparative effectiveness of platelet-rich plasma injections for treating knee joint cartilage degenerative pathology: a systematic review and meta-analysis, *Arch. Phys. Med. Rehabil.* 95 (3) (2014) 562–575.
- [67] S.-J. Jang, J.-D. Kim, S.-S. Cha, Platelet-rich plasma (PRP) injections as an effective treatment for early osteoarthritis, *Eur. J. Orthop. Surg. Traumatol.* 23 (5) (2013) 573–580.
- [68] S. Sampson, M. Reed, H. Silvers, M. Meng, B. Mandelbaum, Injection of platelet-rich plasma in patients with primary and secondary knee osteoarthritis: a pilot study, *Am. J. Phys. Med. Rehabil.* 89 (12) (2010) 961–969.
- [69] A. Dhollander, F. De Neve, K. Almqvist, R. Verdonk, S. Lambrecht, D. Elewaut, G. Verbruggen, P. Verdonk, Autologous matrix-induced chondrogenesis combined with platelet-rich plasma gel: technical description and a five pilot patients report, *Knee Surg. Sports Traumatol. Arthrosc.* 19 (4) (2011) 536–542.
- [70] G. Filardo, E. Kon, M.T.P. Ruiz, F. Vaccaro, R. Guitaldi, A. Di Martino, A. Cenacchi, P.M. Fornasari, M. Marcacci, Platelet-rich plasma intra-articular injections for cartilage degeneration and osteoarthritis: single-versus double-spinning approach, *Knee Surg. Sports Traumatol. Arthrosc.* 20 (10) (2012) 2082–2091.
- [71] F. Cerza, S. Carni, A. Carcangiu, I. Di Vavo, V. Schiavilla, A. Pecora, G. De Biasi, M. Ciuffreda, Comparison between hyaluronic acid and platelet-rich plasma, intra-articular infiltration in the treatment of gonarthrosis, *Am. J. Sports Med.* 40 (12) (2012) 2822–2827.
- [72] M. Sánchez, J. Guadilla, N. Fiz, I. Andia, Ultrasound-guided platelet-rich plasma injections for the treatment of osteoarthritis of the hip, *Rheumatology (Oxford)* 51 (1) (2011) 144–150.
- [73] H. Koga, M. Shimaya, T. Muneta, A. Nimura, T. Morito, M. Hayashi, S. Suzuki, Y.-J. Ju, T. Mochizuki, I. Sekiya, Local adherent technique for transplanting mesenchymal stem cells as a potential treatment of cartilage defect, *Arthritis Res. Ther.* 10 (4) (2008) R84.
- [74] M. Sato, K. Uchida, H. Nakajima, T. Miyazaki, A.R. Guerrero, S. Watanabe, S. Roberts, H. Baba, Direct transplantation of mesenchymal stem cells into the knee joints of Hartley strain guinea pigs with spontaneous osteoarthritis, *Arthritis Res. Ther.* 14 (1) (2012) R31.
- [75] K.H.-T. Bui, T.D. Duong, N.T. Nguyen, T.D. Nguyen, V.T. Le, V.T. Mai, N.L.-C. Phan, D.M. Le, N.K. Phan, P. Van Pham, Symptomatic knee osteoarthritis treatment using autologous adipose derived stem cells and platelet-rich plasma: a clinical study, *Biomed. Res. Ther.* 1 (01) (2014) 02–08.
- [76] Y.-G. Koh, Y.-J. Choi, S.-K. Kwon, Y.-S. Kim, J.-E. Yeo, Clinical results and second-look arthroscopic findings after treatment with adipose-derived stem cells for knee osteoarthritis, *Knee Surg. Sports Traumatol. Arthrosc.* 23 (5) (2015) 1308–1316.
- [77] M. Strioga, S. Viswanathan, A. Darinskas, O. Slaby, J. Michalek, Same or not the same? Comparison of adipose tissue-derived versus bone marrow-derived mesenchymal stem and stromal cells, *Stem Cells Dev.* 21 (14) (2012) 2724–2752.
- [78] C.T. Vangsness Jr, I. Jack Farr, J. Boyd, D.T. Dellaero, C.R. Mills, M. LeRoux-Williams, Adult human mesenchymal stem cells delivered via intra-articular injection to the knee following partial medial meniscectomy: a randomized, double-blind, controlled study, *JBJS* 96 (2) (2014) 90–98.
- [79] C.S. Lee, O.A. Burnsed, V. Raghuram, J. Kalisvaart, B.D. Boyan, Z. Schwartz, Adipose stem cells can secrete angiogenic factors that inhibit hyaline cartilage regeneration, *Stem Cell Res. Ther.* 3 (4) (2012) 35.
- [80] H. Mizuno, M. Tobita, A.C. Uysal, Concise review: adipose-derived stem cells as a novel tool for future regenerative medicine, *Stem Cells* 30 (5) (2012) 804–810.
- [81] P.A. Zuk, M. Zhu, H. Mizuno, J. Huang, J.W. Futrell, A.J. Katz, P. Benham, H.P. Lorenz, M.H. Hedrick, Multilineage cells from human adipose tissue: implications for cell-based therapies, *Tissue Eng.* 7 (2) (2001) 211–228.
- [82] P.A. Zuk, M. Zhu, P. Ashjian, D.A. De Ugarte, J.I. Huang, H. Mizuno, Z.C. Alfonso, J.K. Fraser, P. Benham, M.H. Hedrick, Human adipose tissue is a source of multipotent stem cells, *Mol. Biol. Cell* 13 (12) (2002) 4279–4295.
- [83] J. Buckwalter, Articular cartilage injuries, *Clin. Orthop. Relat. Res.* 402 (2002) 21–37.
- [84] J. Pak, Regeneration of human bones in hip osteonecrosis and human cartilage in knee osteoarthritis with autologous adipose-tissue-derived stem cells: a case series, *J. Med. Case Rep.* 5 (1) (2011) 296.
- [85] J. Pak, J.-J. Chang, J.H. Lee, S.H. Lee, Safety reporting on implantation of autologous adipose tissue-derived stem cells with platelet-rich plasma into human articular joints, *BMC Musculoskelet. Disord.* 14 (1) (2013) 337.
- [86] Y.-G. Koh, S.-B. Jo, O.-R. Kwon, D.-S. Suh, S.-W. Lee, S.-H. Park, Y.-J. Choi, Mesenchymal stem cell injections improve symptoms of knee osteoarthritis, *Arthrosc.: J. Arthrosc. Relat. Surg.* 29 (4) (2013) 748–755.
- [87] Y.-G. Koh, O.-R. Kwon, Y.-S. Kim, Y.-J. Choi, Comparative outcomes of open-wedge high tibial osteotomy with platelet-rich plasma alone or in combination with mesenchymal stem cell treatment: a prospective study, *Arthrosc.: J. Arthrosc. Relat. Surg.* 30 (11) (2014) 1453–1460.
- [88] Y.G. Koh, Y.J. Choi, O.R. Kwon, Y.S. Kim, Second-look arthroscopic evaluation of cartilage lesions after mesenchymal stem cell implantation in osteoarthritic knees, *Am. J. Sports Med.* 42 (7) (2014) 1628–1637.
- [89] Y.S. Kim, Y.J. Choi, D.S. Suh, D.B. Heo, Y.I. Kim, J.-S. Ryu, Y.G. Koh, Mesenchymal stem cell implantation in osteoarthritic knees: is fibrin glue effective as a scaffold? *Am. J. Sports Med.* 43 (1) (2015) 176–185.
- [90] J. Pak, J.H. Lee, K.S. Park, B.C. Jeong, S.H. Lee, Regeneration of cartilage in human knee osteoarthritis with autologous adipose tissue-derived stem cells and autologous extracellular matrix, *BioResearch Open Access* 5 (1) (2016) 192–200.
- [91] P. Wehling, C. Moser, D. Frisbie, C.W. McIlwraith, C.E. Kawcak, R. Krauspe, J.A. Reinecke, Autologous conditioned serum in the treatment of orthopedic diseases, *BioDrugs* 21 (5) (2007) 323–332.
- [92] C.A. Dinarello, R.C. Thompson, Blocking IL-1: interleukin 1 receptor antagonist in vivo and in vitro, *Immunol. Today* 12 (11) (1991) 404–410.
- [93] E.V. Granowitz, B. Clark, J. Mancilla, C. Dinarello, Interleukin-1 receptor antagonist competitively inhibits the binding of interleukin-1 to the type II interleukin-1 receptor, *J. Biol. Chem.* 266 (22) (1991) 14147–14150.
- [94] W.P. Arend, M. Malyak, C.J. Guthridge, C. Gabay, Interleukin-1 receptor antagonist: role in biology, *Annu. Rev. Immunol.* 16 (1) (1998) 27–55.
- [95] W.P. Arend, Interleukin-1 receptor antagonist, *Adv. Immunol.* 54 (1993) 167–227.
- [96] W. Arend, M. Malyak, C. Bigler, J.M. Smith, R. Janson, The biological role of naturally-occurring cytokine inhibitors, *Br. J. Rheumatol.* 30 (1991) 49–52.
- [97] W.P. Arend, D.Y. Leung, IgG induction of IL-1 receptor antagonist production by human monocytes, *Immunol. Rev.* 139 (1) (1994) 71–78.
- [98] W. Arend, M. Smith, R. Janson, F. Joslin, IL-1 receptor antagonist and IL-1 beta production in human monocytes are regulated differently, *J. Immunol.* 147 (5) (1991) 1530–1536.
- [99] H. Meijer, J. Reinecke, C. Becker, G. Tholen, P. Wehling, The production of anti-inflammatory cytokines in whole blood by physico-chemical induction, *Inflamm. Res.* 52 (10) (2003) 404–407.

- [100] A. Frizziero, E. Giannotti, F. Oliva, S. Masiero, N. Maffulli, Autologous conditioned serum for the treatment of osteoarthritis and other possible applications in musculoskeletal disorders, *Br. Med. Bull.* 105 (1) (2013).
- [101] W.P. Arend, M. Malyak, M. Smith, T.D. Whisenand, J.L. Slack, J.E. Sims, J.G. Giri, S.K. Dower, Binding of IL-1 alpha, IL-1 beta, and IL-1 receptor antagonist by soluble IL-1 receptors and levels of soluble IL-1 receptors in synovial fluids, *J. Immunol.* 153 (10) (1994) 4766–4774.
- [102] M. Rutgers, D.B. Saris, W.J. Dhert, L.B. Creemers, Cytokine profile of autologous conditioned serum for treatment of osteoarthritis, in vitro effects on cartilage metabolism and intra-articular levels after injection, *Arthritis Res. Ther.* 12 (3) (2010) R114.
- [103] T. Wright-Carpenter, P. Klein, P. Schäferhoff, H. Appell, L. Mir, P. Wehling, Treatment of muscle injuries by local administration of autologous conditioned serum: a pilot study on sportsmen with muscle strains, *Int. J. Sports Med.* 25 (08) (2004) 588–593.
- [104] A. Baltzer, C. Moser, S. Jansen, R. Krauspe, Autologous conditioned serum (Orthokine) is an effective treatment for knee osteoarthritis, *Osteoarthr. Cartil.* 17 (2) (2009) 152–160.
- [105] R. Altman, E. Asch, D. Bloch, G. Bole, D. Borenstein, K. Brandt, W. Christy, T. Cooke, R. Greenwald, M. Hochberg, Development of criteria for the classification and reporting of osteoarthritis: classification of osteoarthritis of the knee, *Arthritis Rheumatol.* 29 (8) (1986) 1039–1049.
- [106] J. Kellgren, J. Lawrence, Radiological assessment of osteo-arthrosis, *Ann. Rheum. Dis.* 16 (4) (1957) 494.
- [107] M.A. Ismahil, T. Hamid, S.S. Bansal, B. Patel, J.R. Kingery, S.D. Prabhu, Remodeling of the mononuclear phagocyte network underlies chronic inflammation and disease progression in heart failure: critical importance of the cardiopulmonary axis, *Circ. Res.* 113 (2013) 301720 CIRCRESAHA.
- [108] J. Choi, K.W. Minn, H. Chang, The efficacy and safety of platelet-rich plasma and adipose-derived stem cells: an update, *Arch. Plast. Surg.* 39 (6) (2012) 585.
- [109] M. Zhao, C.I. Dumur, S.E. Holt, M.J. Beckman, L.W. Elmore, Multipotent adipose stromal cells and breast cancer development: think globally, act locally, *Mol. Carcinog.* 49 (11) (2010) 923–927.
- [110] L. Prantl, F. Muehlberg, N.M. Navone, Y.H. Song, J. Vykoukal, C.J. Logothetis, E.U. Alt, Adipose tissue-derived stem cells promote prostate tumor growth, *Prostate* 70 (15) (2010) 1709–1715.
- [111] E. Knop, L.E. de Paula, R. Fuller, Platelet-rich plasma for osteoarthritis treatment, *Revista Brasileira de Reumatologia (English Edition)* 56 (2) (2016) 152–164.
- [112] D. Correa, A. Gomez, C. Vargas, E. Turner, M. Carstens, Adipose-derived stromal vascular fraction (SVF) for the treatment of osteoarthritis of the knee, functional outcome and anatomic recovery of the cartilage: a case report, *CellR4* 4 (1) (2016) e1768.
- [113] J. Michalek, R. Moster, L. Lukac, K. Proefrock, M. Petrasovic, J. Rybar, M. Capkova, A. Chaloupka, A. Darinskas, J. Michalek Sr., Autologous adipose tissue-derived stromal vascular fraction cells application in patients with osteoarthritis, *Cell Transpl.* 20 (2015) 1–36.
- [114] P. Gentile, B. De Angelis, M. Pasin, G. Cervelli, C.B. Curcio, M. Floris, C. Di Pasquali, I. Bocchini, A. Balzani, F. Nicoli, Adipose-derived stromal vascular fraction cells and platelet-rich plasma: basic and clinical evaluation for cell-based therapies in patients with scars on the face, *J. Craniofac. Surg.* 25 (1) (2014) 267–272.